

6. Timing for orthodontic force

Orthodontic force is generally less than 300gm, so early mechanical stability is enough for immediate orthodontic force. There is no actually difference in success rate between immediate loading and delayed loading.

NiTi coil spring is recommended for elasticity, because it seldom decay force so that it may apply weak force constantly (Fig.16). In cases like intrusion, with short distance between microimplant and attachment of tooth, elastic thread (Square Thread, Dentos Inc., Daegu, Korea) is useful (Fig.17).

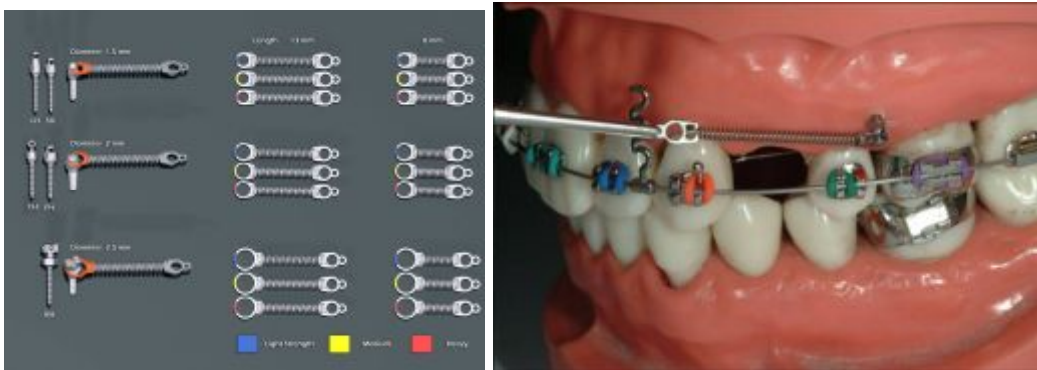


Fig.16. Niti coil springs from Dentos, Inc. Small additional hole makes convenient to handle coil spring.

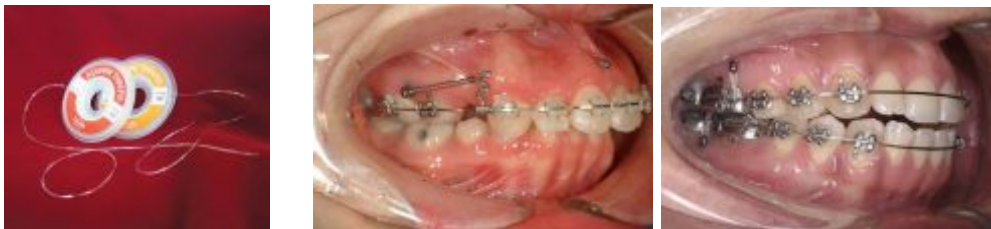

Fig.17. Square elastic threads (Dentos, Inc., Daegu, Korea) may be useful in cases like anterior or posterior intrusion, which power chain or coil spring is not appropriate due to short action range.

7. Root injury and success rate

Most clinicians are afraid of root injury during drilling or installing microimplants between the teeth, but it is not a clinically big problem except for root perforation (Maino et al, 2007). However, failure rate can be increased, if microimplant touched roots or placed near the roots (Kuroda et al;2007-b).

The success rate for maxilla is above 90% and about 85% in mandible in general, if lower success rate has achieved, roots may be possibly contacted when installing microimplants. However, once we failed, we should not give up, since there is another chance to succeed when we insert another site. Though there are some kinds of patients who are tend to reject any kind of foreign bodies, all patients should be informed not only of failure rate but also of host factor before installing microimplants.

8. Removal of microimplants

Even titanium alloys induce osseointegration after placing in the bone, since there is about 90% of titanium in the alloys. Fortunately thin microimplants can be removed easily when rotated counter-installing wise using driver. There is no need to inject for anesthesia, only topical anesthesia is enough, also there is not that much pain even removed without any anesthesia because of no innervation in the bone.

9. Various microimplant application sites depending on the type of tooth movement

1) *En Masse* retraction of anterior teeth in labial fixed appliance

The 1st choice of buccal microimplant site is between the second premolar and first molar roots buccally for anterior *en masse* retraction in extraction cases in both arches. If the 1st microimplant is failed, the 2nd microimplant can be placed between the first molar and second molar roots. A microimplant can be placed in different heights on the gingiva relative to the main arch wire. Of course the microimplant placed near to the occlusal plane, the occlusal plane will rotate clockwise direction in the maxilla and counter clockwise direction in the mandible. Also, microimplant is placed a little away from the archwire, the occlusal plane will rotate in opposite direction. However, so many biomechanical factors, such as height of anterior hook, amount and type of force, diameter of archwire, amount of compensating wire bending, root size and quality of cortical bone etc, are involved during the *en masse* retraction. Thus, for more precise control of occlusal plane during anterior retraction, it's better to place one or two anterior microimplants between incisor roots (Fig.18). Anterior microimplant also can produce lingual root torque effectively as well as prevent extrusion of anterior teeth during *en masse* retraction of anterior teeth.

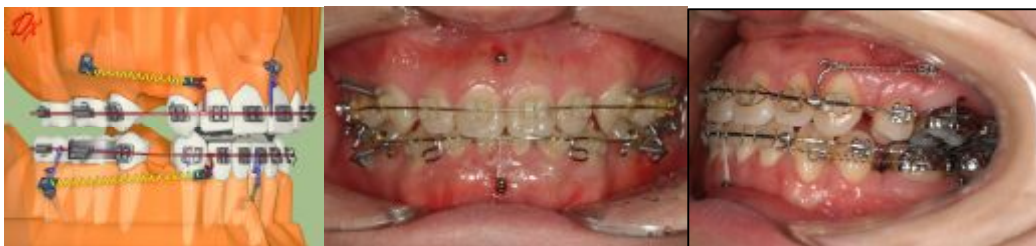

Fig.18. Buccal & labial anterior microimplants for anterior *en masse* retraction in extraction case.

2) *En Masse* retraction of anterior teeth in lingual fixed appliance

The 1st choice of microimplant site for maxillary lingual fixed appliance is between the 1st molar and 2nd molar roots palatally for anterior *en masse* retraction in extraction cases (Fig.19). If the 1st microimplant is failed, the 2nd microimplant can be placed between the first molar and second premolar

roots on the palate. Even maxillary lingual fixed orthodontic treatment, buccal microimplant can be placed between the 1st molar and 2nd molar roots too. Then the 1st molar buccal attachment can be ligated to the microimplant to prevent anchorage loss. In the mandible, it is difficult to place the microimplant in the lingual side and is a little irritable to patient's tongue. So, usually the microimplant can be placed between mandibular 1st molar and 2nd molar roots buccally. Also, the microimplant can be ligated to the 1st molar buccal attachment to reinforce anchorage.

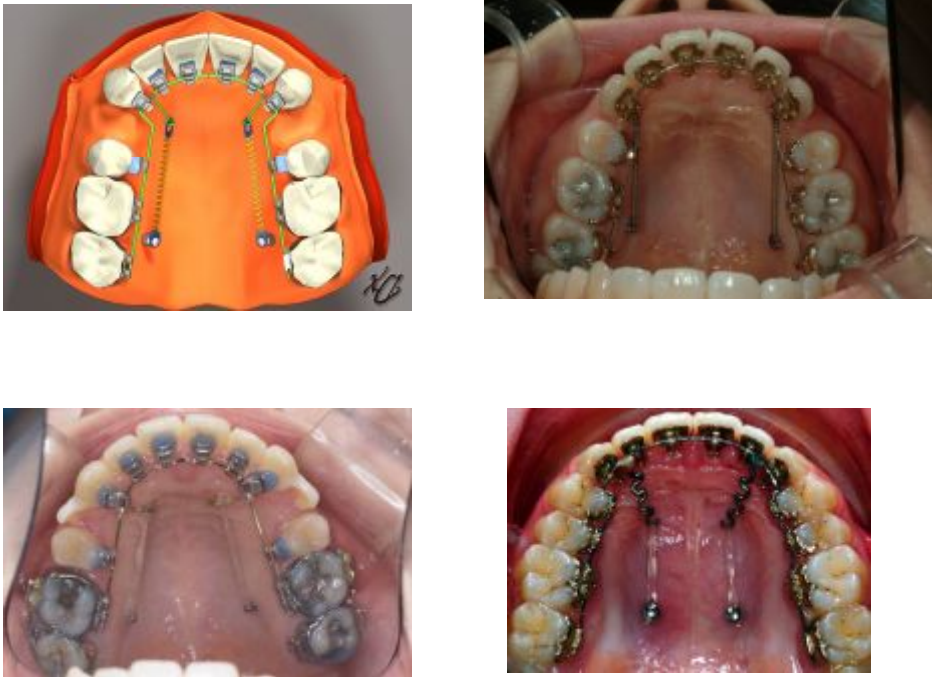

Fig. 19. Palatal alveolar microimplants for en masse retraction in lingual fixed appliance.

3) Openbite correction by intrusion of posterior teeth

If it is possible to intrude molar teeth using microimplants, open bite can be corrected relatively easily, even in skeletal open bite case. Usually, if 1 mm molar intrusion is achieved posteriorly, an anterior openbite will be closed in 2-3mm. Microimplants can be placed between the roots of the second premolar and first molar and/or first molar and second molar either buccally in both arches or palatally in the maxilla for intrusion of molar teeth (Fig.20). Midpalatal microimplant also can be used to intrude posterior teeth. For intrusion, elastomeric thread is useful material to apply the force from the microimplant to the main arch or attachments of molars, if there is short distance between them. Transpalatal arch and lingual arch should be used to prevent buccal tipping of posterior teeth during intrusion.

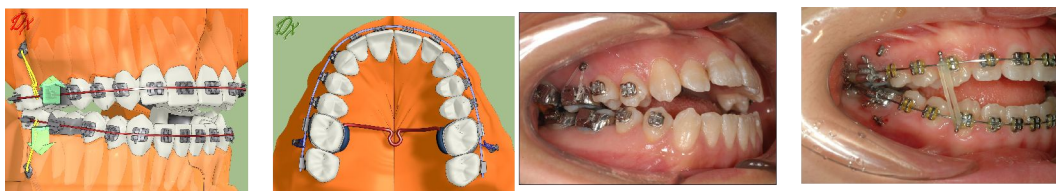

Fig. 20. Posterior buccal microimplants to intrude posterior teeth.

4) Retraction of whole dentition & molar distalization

The entire maxillary or mandibular dentition can be retracted by way of two buccal microimplants after placing between 2nd premolars and 1st molars. The retraction of the entire dentition is more effective in patients who have mesially tipped posterior teeth. If the microimplant touches the adjacent roots during retraction, the first microimplants can be removed, and then the 2nd ones can be placed just distal to the first one. Microimplant (1.2-1.4mm diametr) is small enough to place just near to the 1st one even in between roots (Fig.21 & 22).

Also, tuberosity or retromolar microimplant can be used for retraction of whole mandibular dentition without removal of the 1st microimplant. However, it is a little difficult to place microimplant on the tuberosity or retromolar area due to limited access and thick soft tissue (Fig.23).

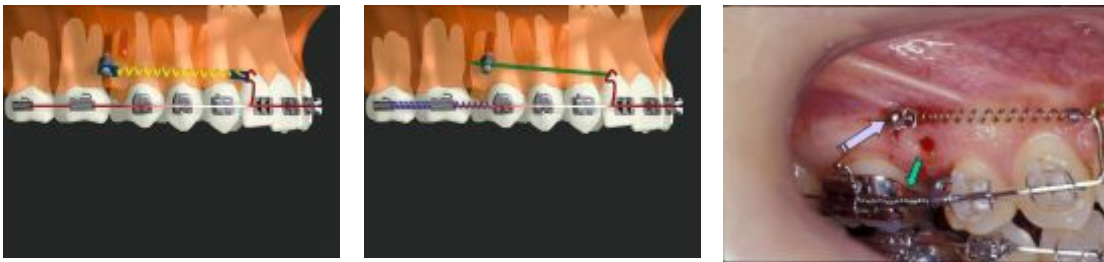


Fig.21. Maxillary buccal microimplants for molar distalization followed by retraction of remaining anterior teeth after placing 2nd microimplant just distal to the 1st one.

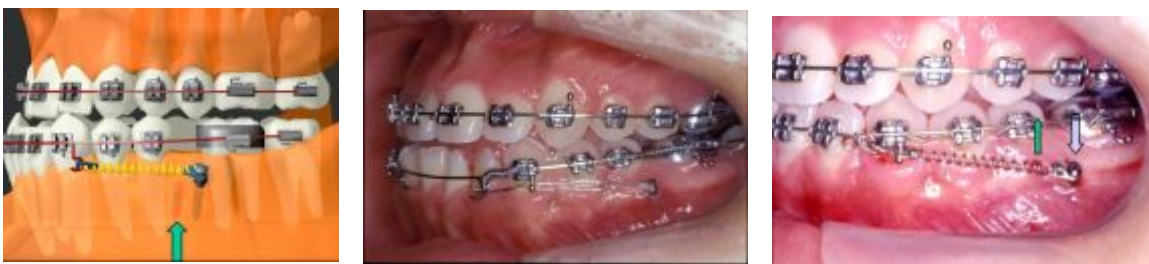

Fig. 22. Mandibular buccal microimplants for molar distalization followed by retraction of remaining anterior teeth after placing 2nd microimplant just distal to the 1st one.

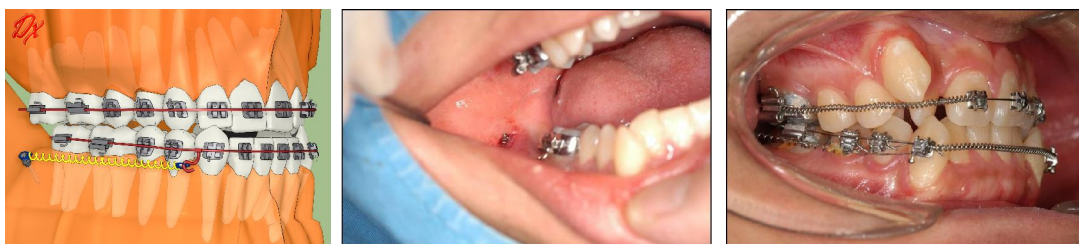

Fig. 23. Retromolar microimplant for retraction of whole mandibular dentition.

5) Molar uprighting, distalizing, protraction and root movement

A single microimplant can be placed on the retromolar area for uprighting of mandibular 2nd molar (Fig 24). However, retromolar single microimplant is difficult for three dimensional tooth movement as well as difficult for placement. However, if there is edentulous area near tipped molar, it is better to place two microimplant on the edentulous area. Bracket or any kind of attachments can be attached to the microimplants using light curing composite resin. Then, rectangular wire can be used for three dimension tooth control, and it is possible to protract and root movement as well as uprighting and distalizing (Fig.25).

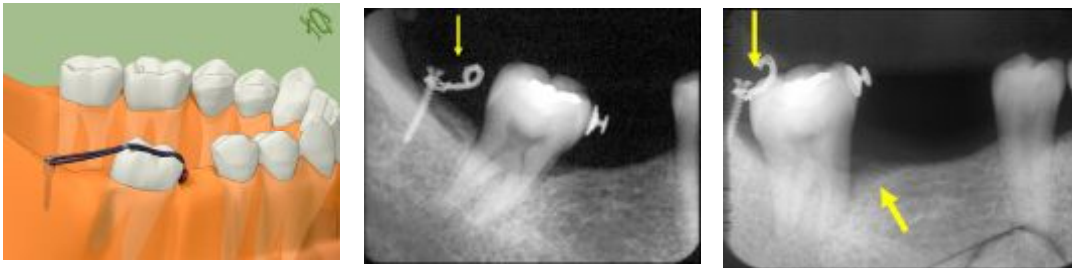


Fig. 24. Single retromolar microimplant for simple molar uprighting.

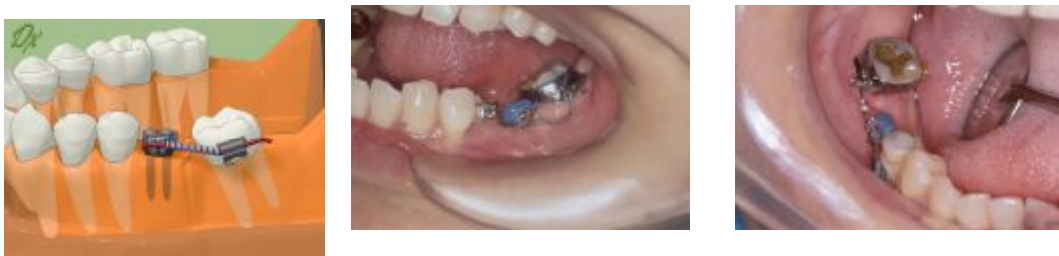

Fig.25. Two microimplants can be placed on the edentulous area and bracket was attached for molar uprighting and protraction.